

# Handling perforations of the sinus membrane

## A new approach using advanced platelet-rich fibrin (A-PRF)

One in four sinus lift procedures can be expected to result in perforations of the Schneiderian membrane. Although the clinical significance of this complication remains controversial, a careful assessment of the risk factors can help us prevent perforations, along with the use of prudent surgical techniques.

Several techniques for repairing the sinus membrane have been proposed which vary depending on the location and size of the perforation. This article will present three case reports involving sinus membrane perforations which were treated using advanced platelet-rich fibrin (A-PRF).

### Incidence

Resorbed alveolar ridges can frequently be found in the posterior maxilla. In these cases, augmentation procedures in the maxillary sinus are often required before implants can be placed. Sinus augmentation is one of the best documented procedures in the literature with predictable long-term success rates regularly exceeding 90%<sup>1-5</sup>.

This is a technique-sensitive procedure, however, and it is not without complications. Perforations of the sinus membrane are the most common complications reported, with a mean incidence rate of 25–30%<sup>6</sup>. In a recent meta-analysis of 1,652 sinus lift procedures reported across 12 studies, the weighted incidence rate of perforation was 23.5% (95% CI), ranging from 3.6% to 41.8%<sup>7</sup>. This disparity may be due to several contributing factors, or even to perforations remaining undetected. As a practical conclusion, we can therefore expect to encounter one membrane perforation in every four sinus lift procedures.

### Risk factors

Perforations can occur as a result of human error at a variety of stages, including when the bone is drilled; the Schneiderian membrane detached; or the

graft filled. In addition, perforations are frequently encountered in cases involving anatomic variations such as thinner or thicker membranes; the presence of septae; and sinus pathology<sup>8,13,14</sup>. Decreased incidence was recorded in several studies where piezoelectric instrumentation was used<sup>7</sup>.

### Clinical consequences

The clinical consequences of sinus membrane perforations have not yet been clearly established. It is well known that implants perforating the sinus floor and protruding up to 3mm into the sinus cavity do not show lower success rates<sup>15</sup>. When the Schneiderian membrane is perforated, however, the graft material is not confined and could be dislodged and neo-vascularisation disturbed, thus hindering bone regeneration. Moreover, it has been shown that the sinus membrane possesses osteogenic capabilities; contains stem cells; and participates in bone formation after the sinus floor has been lifted<sup>16,17</sup>.

Membrane perforations have been linked to higher postoperative complications; impaired graft healing; and implant failure<sup>1,6,9,12</sup>. Other studies, however, have found no correlation between them<sup>7,8,11</sup>. A proper diagnosis and careful surgical management of the membrane seem to be the best methods for handling perforations.

### Classification and handling

Membrane perforations have been classified into five categories, depending on their location and how difficult they are to repair<sup>18</sup>. This classification was retroactively simplified by the same authors<sup>19</sup>. Based on the size of the perforations, Hernández-Alfaro and colleagues defined three types:

- less than 5mm
- between 5mm and 10mm
- more than 10mm<sup>6</sup>

### Alberto Salgado Velázquez

received the Best Academic Award from the University Complutense Madrid in 2001. There, he also qualified as a Master of Oral Surgery and Master of Implants. He is currently a professor of the Master of Implants course at the Universidad Miguel Hernández de Elche. Dr Salgado is also a member of the Aula Dental Avanzada group.



### Lino Esteve Colomina

received his DMD from University Complutense Madrid in 1980 and has been working in the field of implant dentistry since 1988. He is a past president of the College of Dentists and the Group of Dental Studies in Alicante, and a board member of the Sociedad Española de Implantes (SEI). He was the chairman of the SEI's 20th international congress. Since 2012, Dr Esteve has been the director of the postgraduate programme in oral implantology at the Universidad Miguel Hernández.

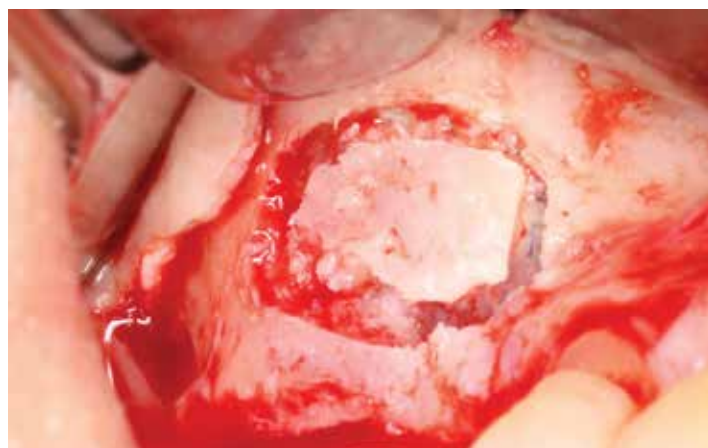

Figure 1.1.1

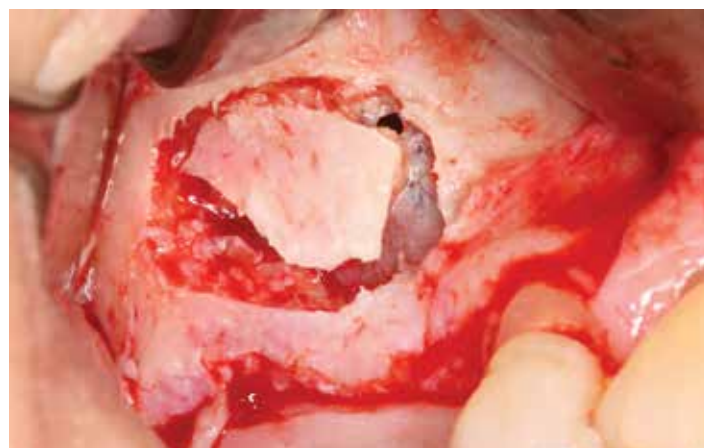


Figure 1.1.2

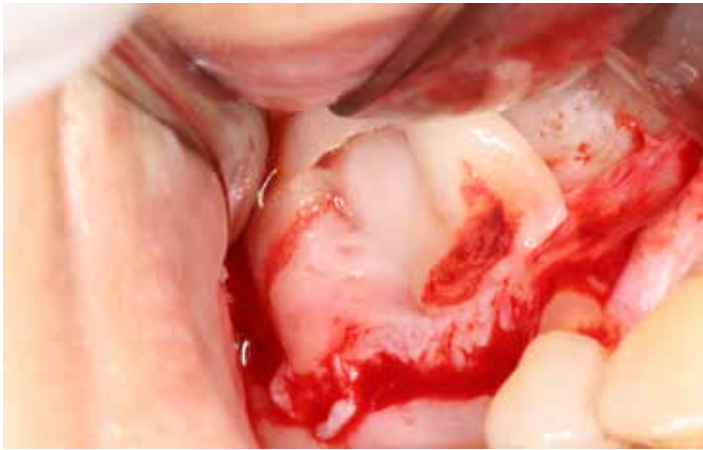

Figure 1.3.1

As a general rule, the bigger the perforation, the more difficult it is to manage. Various methods for repairing perforations have been proposed<sup>6, 9, 20-23</sup>.

**Small (<5mm) perforations** can often self-resolve because of folding that occurs when the Schneiderian membrane is reflected.

**Medium (5–10mm) perforations** must be occluded with the use of collagen tape or a collagen membrane. Some authors have also recommended suturing the perforation, although this approach is difficult to perform. Sometimes, by extending the osteotomy, the Schneiderian membrane can be reflected beyond the margins of the perforation.

A resorbable membrane can be inserted into the sinus cavity with its ends extruding from the window to be secured to the bony borders with fixation tacks. Thus a containing pouch for the graft material is created.

**Large (>10mm) perforations** must be covered by means of a lamellar bone sheet or a bone block. A pedicled buccal fat pad flap has also been suggested.

#### Our technique

We strongly recommend the use of advanced platelet-rich fibrin (A-PRF) to repair any type of sinus membrane perforation. This paper will present three cases involving different perforations, all of which were treated using A-PRF.

#### Case 1: small perforation

During the elevation of the sinus membrane, a small class I perforation occurred in the superior medial corner of the window (Figure 1.1). We were able to proceed with the elevation without enlarging the hole and lifted the bony wall into the sinus cavity like a trap door (Figure 1.2).

Because the perforation was small, no collagen membrane was needed. An A-PRF membrane was sufficient to protect the upper space and repair the barrier (Figure 1.3). Next, the space under the repaired membrane was filled with biomaterial; another A-PRF membrane and a collagen membrane were placed to protect the graft laterally (Figures 1.4–1.5).

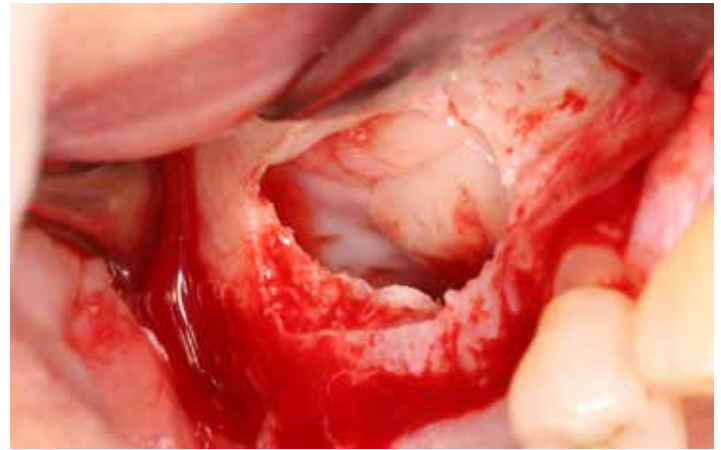

Figure 1.3.2

#### Case 2: multiple perforations

The patient presented with a distobuccal root of tooth 26 on the distal aspect of the lateral bony wall of the sinus and was completely asymptomatic. Direct extraction could not be performed in case the membrane was torn. We therefore performed an osteotomy around the root using piezosurgery to create the bony window (Figure 2.1). The Schneiderian membrane was then detached and two small perforations occurred; one was class I, the other class II (see arrows on Figure 2.2).

We were then able to isolate and remove the root without further damage to the membrane. The bony wall was reflected and the membrane was folded to provide a suitable roof for the augmented subantral space (Figure 2.3). An A-PRF membrane was applied and moulded towards the new roof to thicken it. This was easily achieved due to the adherent characteristics of this membrane (Figure 2.4).

Because there were two different perforations, the roof needed to be strengthened further. To do so, we placed a resorbable collagen membrane to create a self-containing space and filled it with bovine bone granules (Figure 2.5).

To cover the lateral window, we placed another A-PRF membrane and a collagen membrane; repositioned the flap; and closed the wound with interrupted sutures (Figure 2.6).

#### Case 3: large perforation

In the third case, the Schneiderian membrane began to tear in the inferior border forming a class III perforation, and then a new large perforation measuring nearly 20mm occurred in the superior border (Figure 3.1).

To manage this case we found the following approach very beneficial:

- keep the excised bony wall and try to use it in the new barrier which will be created (Figure 3.2)
- place up to six A-PRF membranes which will adhere to bone
- perform the Valsalva manoeuvre. A positive result indicates that a new barrier was successfully created (Figure 3.3)
- to strengthen the barrier, add a resorbable collagen membrane (Figure 3.4). Our rationale for this is that an A-PRF membrane can be expected to last up to 4 weeks – half the time the Schneiderian membrane takes to regenerate (about 8 weeks)
- insert another collagen membrane with its borders extruding from the bony window
- ensure the creation of a self-containing space which is ready to receive the graft, as described by Fugazzotto & Vlassis<sup>18, 19</sup> (Figure 3.5)
- finally, cover the graft laterally with an A-PRF membrane and another collagen membrane above it and suture the wound (Figure 3.6)

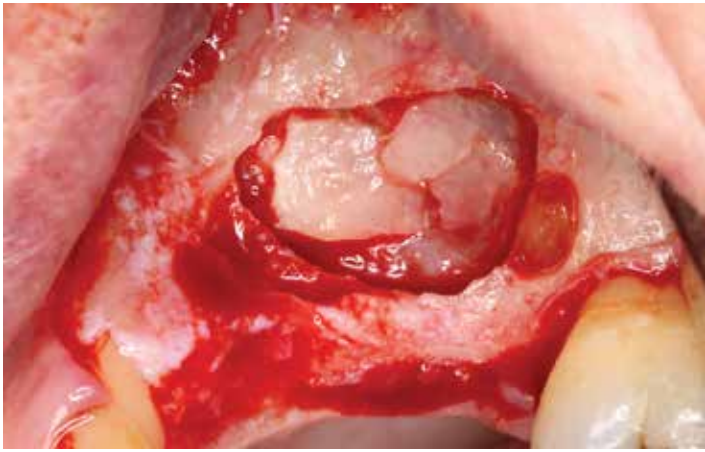


Figure 2.2.1

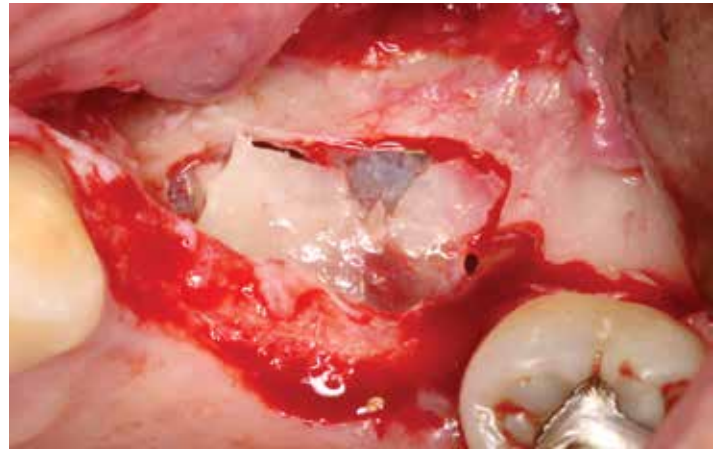


Figure 2.2.2

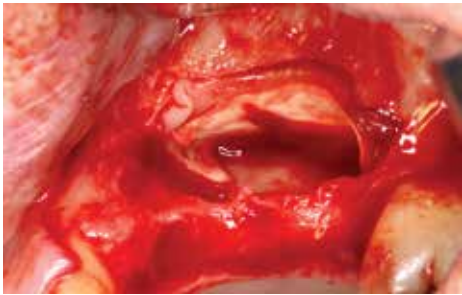


Figure 2.5.1

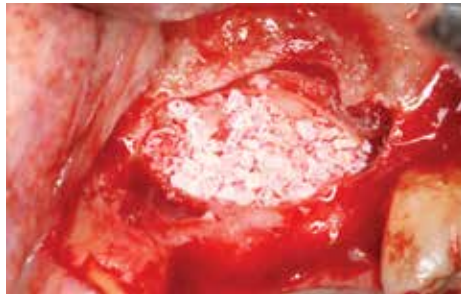


Figure 2.5.2

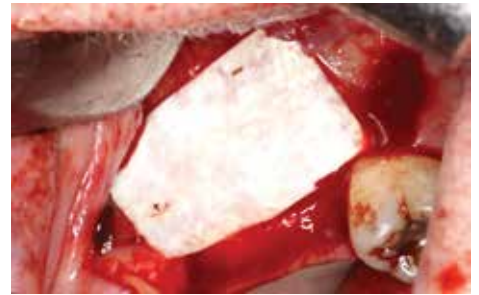


Figure 2.6.2

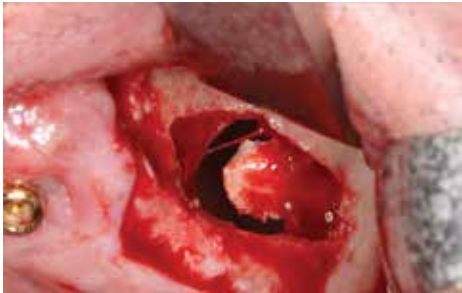

Figure 3.2.1

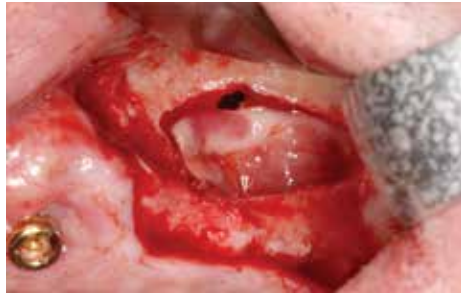

Figure 3.3.1

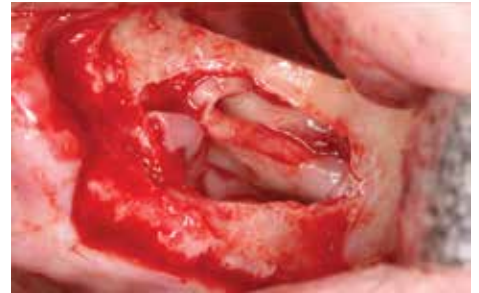

Figure 3.3.2

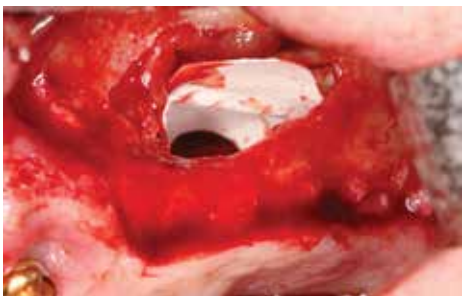


Figure 3.5.1

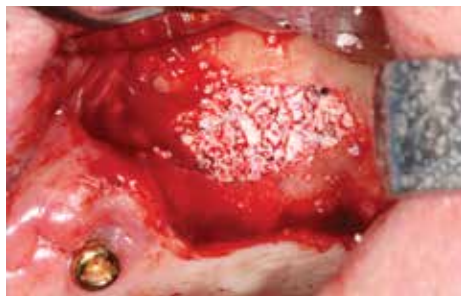

Figure 3.5.2

View the full set of figures and references at [eao.org/inspyred](http://eao.org/inspyred)

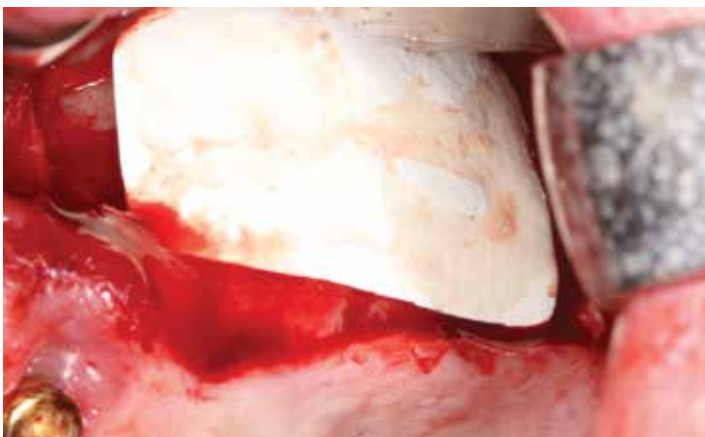


Figure 3.6.1

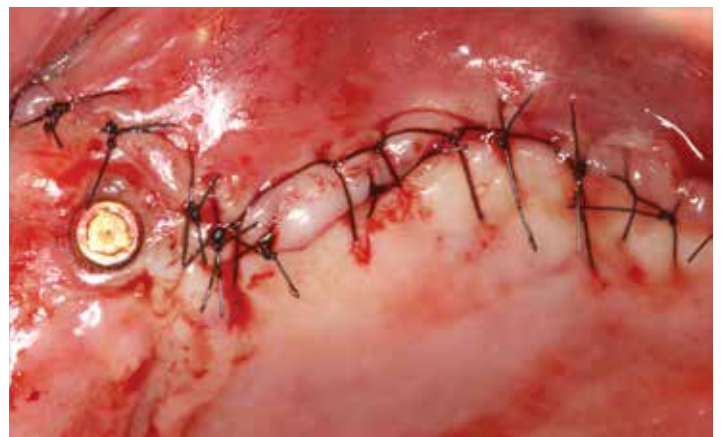

Figure 3.6.2